



PATIENT

Nubbers Tallet

SPECIES

Feline

BREED

Manx

SEX

FS

AGE

12 years

WEIGHT

6 #

INTERPRETED BY

Remo Lobetti, BVSc,
MMedVet (Med),
PhD, Dipl. ECVIM

**IMAGING
PERFORMED BY**

Brent Crutchfield,
DVM

HOSPITAL NAME

Treasure Coast
Animal Emergency

REFERRING VET

Angela Cail

INVOICE

304070

DATE

4/3/23

PRESENTING CLINICAL SIGNS

History: Acute onset vomiting, gastric obstruction.

Physical Examination: N/A.

Urinalysis: N/A.

CBC: N/A

Serum Biochemistry: N/A.

Radiographic Findings: N/A.

ULTRASONOGRAPHIC EXAMINATION OF THE ABDOMEN

Urinary System

Full urinary bladder with a normal thickness (0.1 cm) and appearance of the wall. Small amount of floating hyperechogenic sediment present. No uroliths evident.

Normal trigone area, proximal urethra, and iliac blood vessels.

Normal iliac lymph nodes. Ureters not visualized.

Normal renal size (left 3.3 cm, right 4.1 cm) with increased echogenic appearance, some loss of cortico-medullary differentiation, and normal pelvis and capsule.

Reproductive System

N/A.

Adrenal Glands

Normal shape, echogenic appearance, position, and size. Right 0.48 cm.

Spleen

Normal size and echogenic appearance. Smooth homogenous parenchyma, regular capsule, and normal vasculature. No evidence of inflammatory, neoplastic, infarction, or infiltrative changes noted.

Liver

Normal size, echogenic appearance portal markings, and regular curvilinear capsule. No nodules or masses evident.

Gall bladder

Full gall bladder containing small amount of hyperechogenic sediment. Thickened (0.2 cm) and hyperechogenic appearance of the gall bladder wall. Thickened appearance of the bile duct wall but with no dilation.



PATIENT

Nubbers Tallet

SPECIES

Feline

BREED

Manx

SEX

FS

AGE

12 years

WEIGHT

6 #

INTERPRETED BY

Remo Lobetti, BVSc,
MMedVet (Med),
PhD, Dipl. ECVIM

**IMAGING
PERFORMED BY**

Brent Crutchfield,
DVM

HOSPITAL NAME

Treasure Coast
Animal Emergency

REFERRING VET

Angela Cail

INVOICE

304070

DATE

4/3/23

Gastrointestinal

Normal appearance of the gastro-esophageal junction, duodenum, small intestine, ileo-cecal junction, and colon with no loss of layering, normal wall thickness (duodenum 0.21 cm, colon 0.17 cm) and peristalsis, and no distension of the lumen. Shadowing hyperechogenic material (1.7 cm) and fluid within the stomach. Normal thickness (0.3 cm) and appearance of the gastric wall.

Pancreas

Normal size and echogenic appearance. Regular capsule. Normal echogenic appearance of the mesentery and fat surrounding the pancreas.

Free Abdomen

No mesenteric lymphadenomegaly.
Small amount of acellular ascites present.

ULTRASONOGRAPHIC FINDINGS

Primary findings:

- Gastric foreign body.
- Ascites.

Secondary findings:

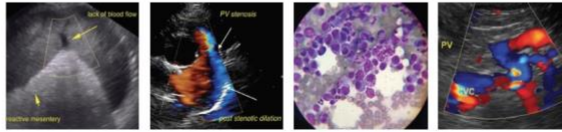
- Gall and urinary bladder sediment.
- Previous cholecystitis.
- Age-related renal changes.

INTERPRETATION OF THE FINDINGS & FURTHER RECOMMENDATIONS

The appearance of the stomach is indicative of gastric obstruction.

The most likely etiology for the ascites would be secondary to the gastric obstruction.

Further assessment/therapy would be gastrotomy.



PATIENT

Nubbers Tallet

SPECIES

Feline

BREED

Manx

SEX

FS

AGE

12 years

WEIGHT

6 #

INTERPRETED BY

Remo Lobetti, BVSc,
MMedVet (Med),
PhD, Dipl. ECVIM

IMAGING PERFORMED BY

Brent Crutchfield,
DVM

HOSPITAL NAME

Treasure Coast
Animal Emergency

REFERRING VET

Angela Cail

INVOICE

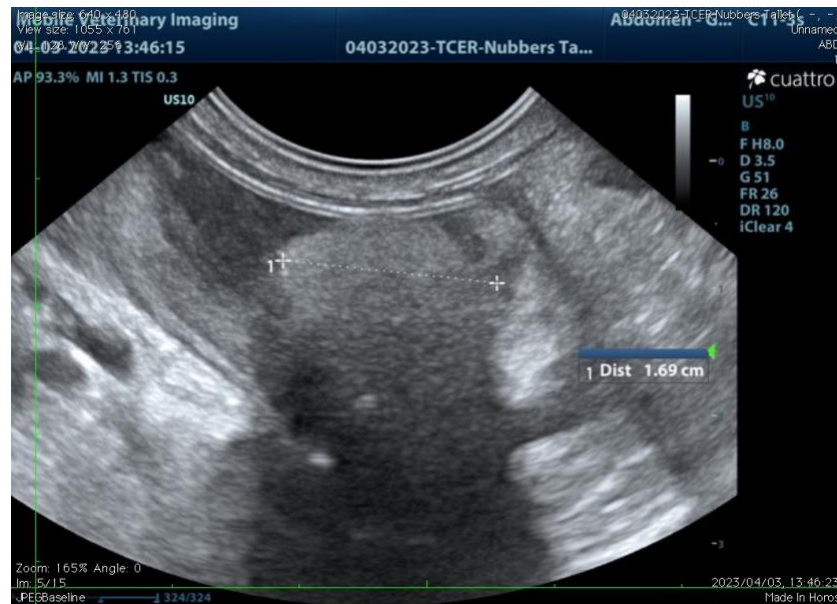
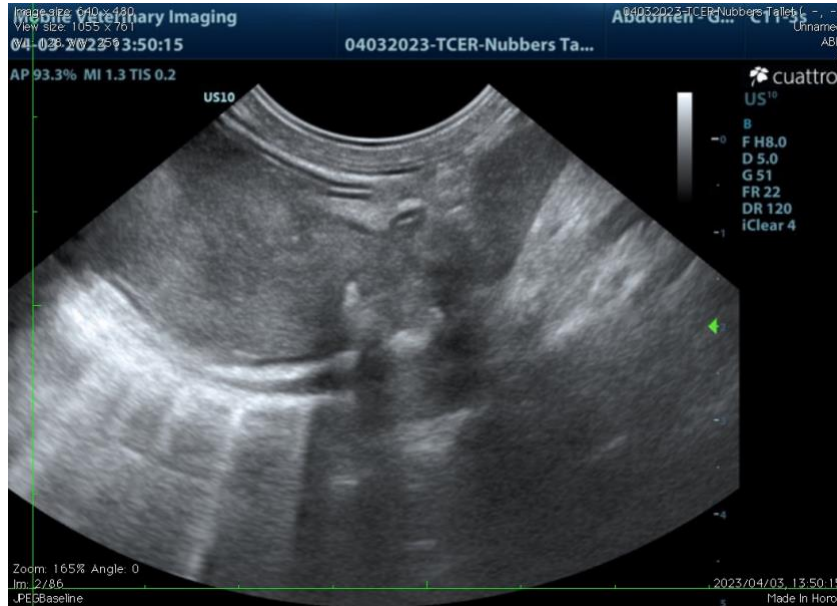304070

DATE

4/3/23

IMAGES

Stomach





PATIENT

Nubbers Tallet

SPECIES

Feline

BREED

Manx

SEX

FS

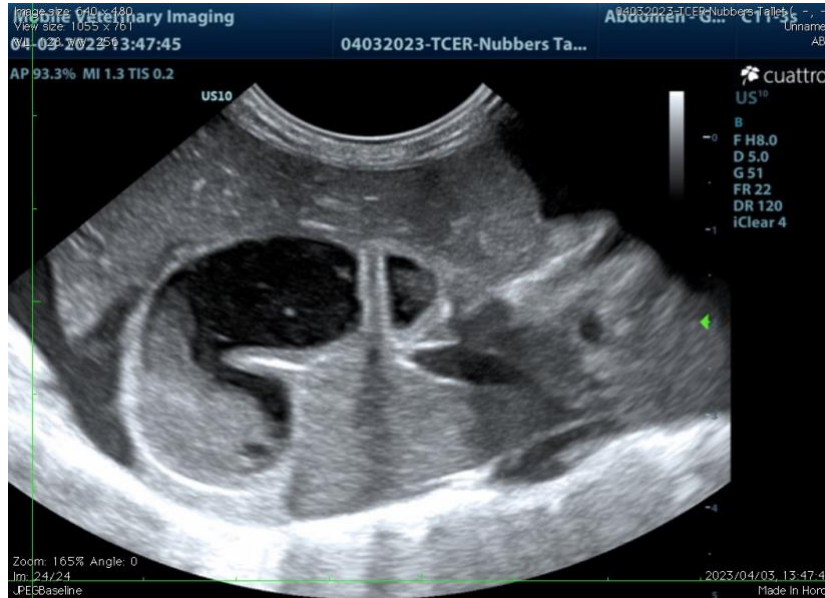AGE

12 years

WEIGHT

6 #

Gall bladder/bile duct



INTERPRETED BY

Remo Lobetti, BVSc,
MMedVet (Med),
PhD, Dipl. ECVIM

The information and recommendations provided are based on the images presented by the referring veterinarian. No evaluation can be communicated regarding pathology that was not visible in the image/video clips provided.

Thank you for this referral. If the clinical or image interpretation does not parallel your findings or if I can be of any further assistance please contact me.

IMAGING PERFORMED BY

Brent Crutchfield,
DVM

Remo Lobetti, BVSc, MMedVet (Med), PhD, Dipl. ECVIM (Internal Medicine)
rlobetti@mweb.co.za

HOSPITAL NAME

Treasure Coast
Animal Emergency

REFERRING VET

Angela Cail

INVOICE

304070

DATE

4/3/23